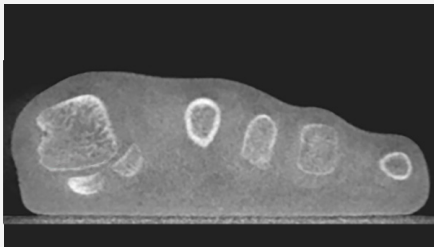



Weight Bearing CT Imaging for Podiatry

Low Dose | Comfortable Standing Position | Quick Scan Times

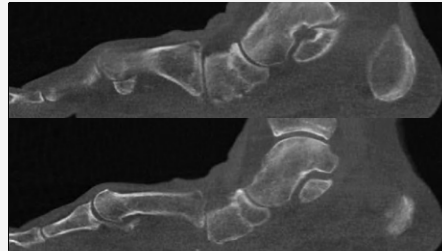
Common Indications

Hallux Valgus



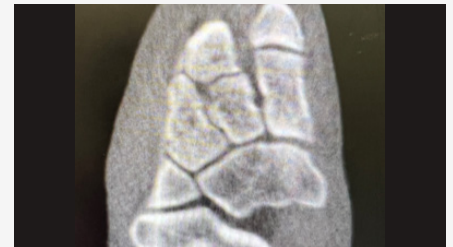- Assess rotation (pronation) of the 1st metatarsal.
- Assess the position of the sesamoids and degenerative changes at the metatarsosesamoid joints.
- Assess congruency and degenerative changes at the 1st MTP joint.

Midfoot Arthritis



- Provide a clearer assessment of degenerative changes and joint space narrowing within the midfoot joints, which is normally impaired due to the natural overlap of adjacent midfoot bones viewed two-dimensionally with conventional radiography.¹

Lisfranc Injuries



- Better characterize bony injuries².
- Evaluate the 3D Lisfranc joint complex under physiologic load.
- Identify subtle Lisfranc injuries by effectively differentiating between stable and unstable Lisfranc injuries³.

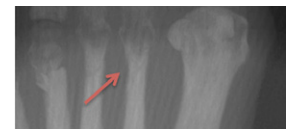Fractures

35% improved fracture detection and 2-fold improved identification of complex fracture over X-Ray.⁴

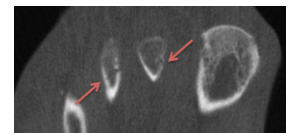


“ A plain X-Ray in many cases will not show small fractures in their early stages of presentation. For this reason, they are often misdiagnosed and mistreated. A low dose Cone Beam CT scan of the foot is very valuable in these situations.

David J. Soomekh, DPM
Sports Medicine & Reconstructive Foot & Ankle Surgery
Foot & Ankle Specialty Group, Beverly Hills, CA

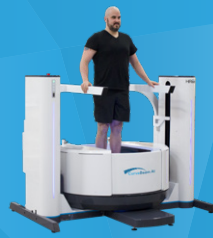

X-Ray



Cone Beam CT

(1) Sripanich Y, Steadman J, Krähenbühl N, Rungprai C, Mills MK, Saltzman CL, Barg A. Asymmetric lambda sign of the second tarsometatarsal joint on axial weight-bearing cone-beam CT scans of the foot: preliminary investigation for diagnosis of subtle ligamentous Lisfranc injuries in a cadaveric model. *Skeletal Radiol.* 2020 Oct;49(10):1615-1621. doi: 10.1007/s00256-020-03445-5. Epub 2020 May 11. PMID: 32394072.
 (2) Sripanich Y, Weinberg M, Krähenbühl N, Rungprai C, Saltzman CL, Barg A. Change in the First Cuneiform-Second Metatarsal Distance After Simulated Ligamentous Lisfranc Injury Evaluated by Weightbearing CT Scans. *Foot Ankle Int.* 2020 Nov;41(11):1432-1441. doi: 10.1177/1071100720938331. Epub 2020 Aug 20. PMID: 32819160.
 (3) Lange, B., & Voldby, H. (2022, February 24). Webinar recap: WBCT scans of potentially unstable. CurveBeam AI. Retrieved March 30, 2023, from <https://curvebeamai.com/webinars/webinar-recapwbct-scans-of-potentially-unstable-weberbser2-fractures/>
 (4) Diagnostic Value of Cone Beam Computed Tomography (CBCT) in Occult Scaphoid and Wrist Fractures Christophe Borel et al, <https://pubmed.ncbi.nlm.nih.gov/29153368/>.

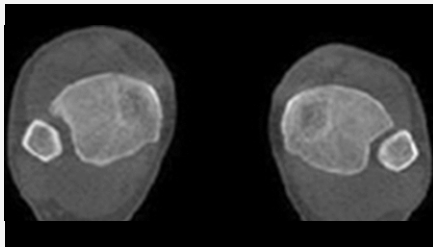


Weight Bearing CT Imaging for Orthopedics

Low Dose | Comfortable Standing Position | Quick Scan Times

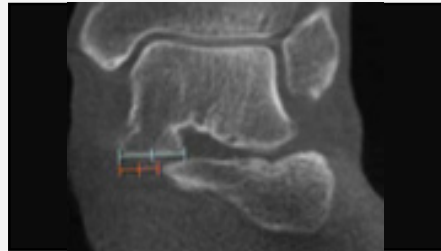
Common Indications

Syndesmosis



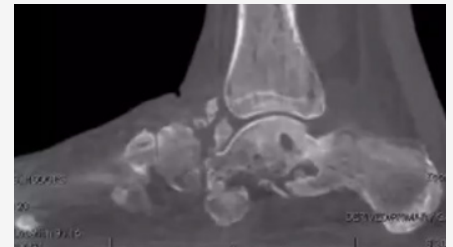- Provide increased sensitivity and specificity over radiographs¹.
- Differentiate pathology from natural variability in patient anatomy via contralateral comparison to uninjured ankle as internal control².
- Help detect subtle syndesmosis injuries¹.

Flat Foot



- Provide an assessment of important anatomical markers of pronounced hindfoot deformity and peritalar subluxation (PTS), difficult to visualize on conventional two-dimensional radiographs².
- Allow for accurate evaluation of subtalar joint subluxation as well as sinus tarsi and subfibular impingement³.

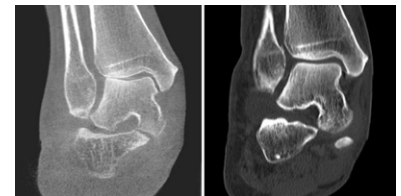
Charcot Foot



- 35% improved fracture detection and 2-fold improved identification of complex fracture over X-Ray.⁴
- CBCT help in the evaluation of the fracture healing process which X-Ray can over or under-estimate.⁵

The Weight Bearing Difference

A 58-year-old patient with significant ankle pain sought a consultation with Dr. Walther. The patient had seen several orthopedic surgeons, one of whom had prescribed orthotics. However, the orthotics did not alleviate her pain. Her supine medical CT (MDCT) scan denoted only minimal arthritis. The patient could not get an MRI due to her pacemaker. Dr. Walther ordered a weight bearing CT (WBCT) scan, which revealed significantly reduced joint space. He performed a successful total ankle replacement on the patient three months later.



Cone Beam CT

Supine CT



“ A WBCT exam of the ankle joint and the foot allows a completely new evaluation of many deformities. It allows axis misalignments, joint instabilities, or osteoarthritis to be better classified. ”

Dr. Markus Walther, MD
Foot and Ankle MD

(1) Lintz F, Bernasconi A, Ferkel EI. Can Weight-Bearing Computed Tomography Be a Game-Changer in the Assessment of Ankle Sprain and Ankle Instability? *Foot Ankle Clin.* 2023 Jun;28(2):283-295. doi: 10.1016/j.fcl.2023.01.003. PMID: 37137623.
 (2) Hagemeyer NC, Chang SH, Abdelaziz ME, Casey JC, Waryasz GR, Guss D, DiGiovanni CW. Range of Normal and Abnormal Syndesmosis Measurements Using Weightbearing CT. *Foot Ankle Int.* 2019 Dec;40(12):1430-1437. doi: 10.1177/1071100719866831. Epub 2019 Aug 23. PMID: 31442094(2) de Cesar Netto C, Myerson MS, Day J, Ellis SJ, Hintermann B, Johnson JE, Sangeorzan BJ, Schon LC, Thordarson DB, Deland JT. Consensus for the Use of Weightbearing CT in the Assessment of Progressive Collapsing Foot Deformity. *Foot Ankle Int.* 2020 Oct;41(10):1277-1282. doi: 10.1177/1071100720950734. Epub 2020 Aug 27. PMID: 32851880.
 (3) Jeng CL, Rutherford T, Hull MG, Cerrato RA, Campbell JT. Assessment of Bony Subfibular Impingement in Flatfoot Patients Using Weight-Bearing CT Scans. *Foot Ankle Int.* 2019 Feb;40(2):152-158. doi: 10.1177/1071100718804510. Epub 2018 Oct 8. PMID: 30293451.
 (4) Wukich DK, Sung W, Wipf SA, Armstrong DG. The consequences of complacency: managing the effects of unrecognized Charcot feet. *Diabet Med.* 2011 Feb;28(2):195-8. doi: 10.1111/j.1464-5491.2010.03141.x. PMID: 21219429.
 (5) Posadzky M, Desimpel J, Vanhoenacker F. Cone beam CT of the musculoskeletal system: clinical applications. *Insights Imaging.* 2018 Feb;9(1):35-45. doi: 10.1007/s13244-017-0582-1. Epub 2018 Jan 4. PMID: 29302798; PMCID: PMC5825310.

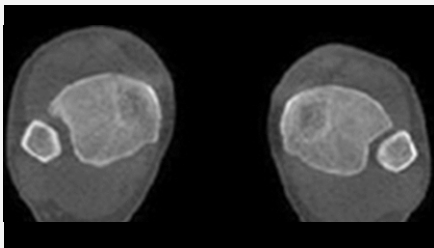


Weight Bearing CT Imaging Sports Medicine

Low Dose | Comfortable Standing Position | Quick Scan Times

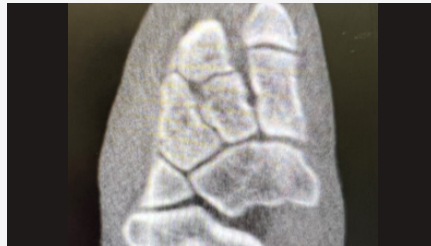Common Indications

Syndesmosis



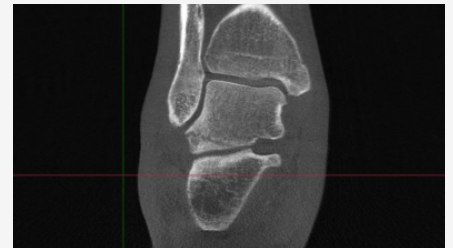- Provide increased sensitivity and specificity over radiographs¹.
- Differentiate pathology from natural variability in patient anatomy via contralateral comparison to uninjured ankle as internal control².
- Help detect subtle syndesmosis injuries¹.

Lisfranc Injuries



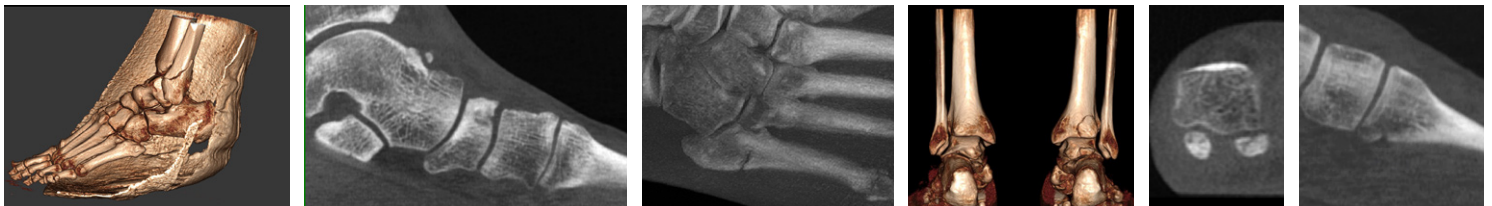
- Better characterize bony injuries³.
- Evaluate the 3D Lisfranc joint complex under physiologic load⁴.
- Identify subtle Lisfranc injuries by effectively differentiating between stable and unstable Lisfranc injuries⁵.

Fractures



- Assist in early detection and aid in an informed plan for early intervention, reducing complication risks⁶.
- Be used to monitor progression of deformity and help determine appropriate stage in which to surgically intervene, with the goal of preventing ulceration and infection⁷.

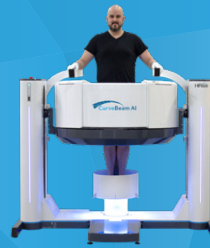35% improved fracture detection⁸



“ I now CT every ankle fracture, and I have been surprised at the variability. ”

Dr. Martin O'Malley, MD
Team Orthopedist
Brooklyn Nets, New York, NY

(1) Lintz F, Bernasconi A, Ferkel EI. Can Weight-Bearing Computed Tomography Be a Game-Changer in the Assessment of Ankle Sprain and Ankle Instability? *Foot Ankle Clin.* 2023 Jun;28(2):283-295. doi: 10.1016/j.fcl.2023.01.003. PMID: 37137623.
 (2) Hagemeyer NC, Chang SH, Abdelaziz ME, Casey JC, Waryasz GR, Guss D, DiGiovanni CW. Range of Normal and Abnormal Syndesmotic Measurements Using Weightbearing CT. *Foot Ankle Int.* 2019 Dec;40(12):1430-1437. doi: 10.1177/1071100719866831. Epub 2019 Aug 23. PMID: 31442094
 (3) Sripanich Y, Weinberg M, Krähenbühl N, Rungprai C, Saltzman CL, Barg A. Change in the First Cuneiform-Second Metatarsal Distance After Simulated Ligamentous Lisfranc Injury Evaluated by Weightbearing CT Scans. *Foot Ankle Int.* 2020 Nov;41(11):1432-1441. doi: 10.1177/1071100720938331. Epub 2020 Aug 20. PMID: 32819160.
 (4) Bhimani R, Sornsakrin P, Ashkani-Esfahani S, Lubberts B, Guss D, De Cesar Netto C, Waryasz GR, Kerkhoffs GMMJ, DiGiovanni CW. Using area and volume measurement via weightbearing CT to detect Lisfranc instability. *J Orthop Res.* 2021 Nov;39(11):2497-2505. doi: 10.1002/jor.24970. Epub 2021 Jan 6. PMID: 33368556.
 (5) Lange, B., & Voldby, H. (2022, February 24). Webinar recap: WBCT scans of potentially unstable. CurveBeam AI. Retrieved March 30, 2023, from <https://curvebeamai.com/webinars/webinar-recapwbct-scans-of-potentially-unstable-weber-ser2-fractures/>
 (6) Diagnostic Value of Cone Beam Computed Tomography (CBCT) in Occult Scaphoid and Wrist Fractures Christophe Borel et al, <https://pubmed.ncbi.nlm.nih.gov/29153368/>.
 (7) Posadzky M, Desimpel J, Vanhoenacker F. Cone beam CT of the musculoskeletal system: clinical applications. *Insights Imaging.* 2018 Feb;9(1):35-45. doi: 10.1007/s13244-017-0582-1. Epub 2018 Jan 4. PMID: 29302798; PMCID: PMC5825310.
 (8) Diagnostic Value of Cone Beam Computed Tomography (CBCT) in Occult Scaphoid and Wrist Fractures Christophe Borel et al, <https://pubmed.ncbi.nlm.nih.gov/29153368/>.

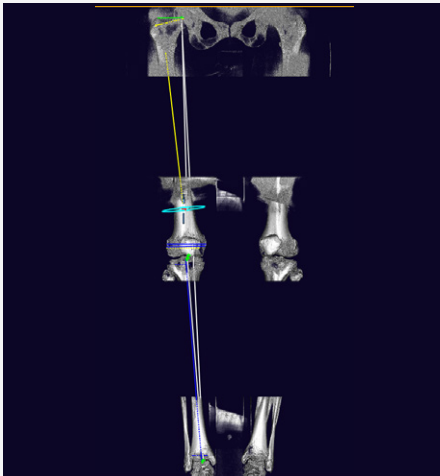


Weight Bearing CT Imaging for Orthopedics

Low Dose | Comfortable Standing Position | Quick Scan Times

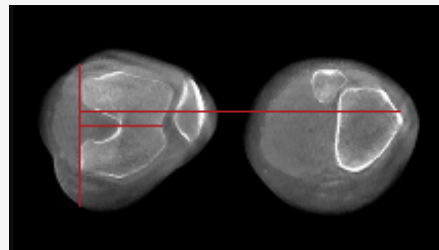
Common Indications

Osteotomy Planning



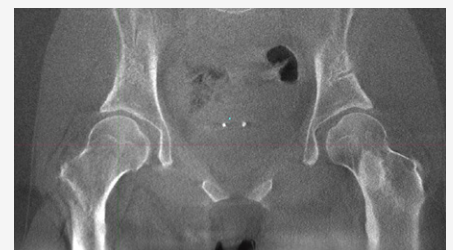- Assess weight bearing alignment and 3D axial rotation in single radiology exam.

Patellar Instability



- Assess patellar stability under muscular contraction and flexion¹.
- Measure femortibial rotation, tibial tuberosity-trochlear groove distance, and lateral patellar tilt angle in weight bearing three dimensions¹.

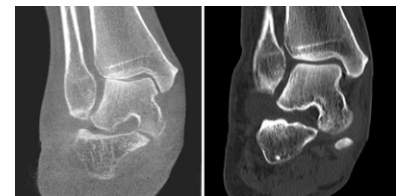Hip Dysplasia



- May be able to visualize changes in measure of hip instability not detected by supine views².

The Weight Bearing Difference

A 58-year-old patient with significant ankle pain sought a consultation with Dr. Walther. The patient had seen several orthopedic surgeons, one of whom had prescribed orthotics. However, the orthotics did not alleviate her pain. Her supine medical CT (MDCT) scan denoted only minimal arthritis. The patient could not get an MRI due to her pacemaker. Dr. Walther ordered a weight bearing CT (WBCT) scan, which revealed significantly reduced joint space. He performed a successful total ankle replacement on the patient three months later.



Cone Beam CT

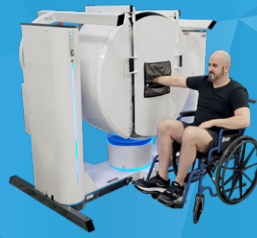Supine CT



“ A WBCT exam of the ankle joint and the foot allows a completely new evaluation of many deformities. It allows axis misalignments, joint instabilities, or osteoarthritis to be better classified. ”

Dr. Markus Walther, MD
Foot and Ankle MD

(1) Conti, Matthew S. MD; Ellis, Scott J. MD. Weight-bearing CT Scans in Foot and Ankle Surgery. Journal of the American Academy of Orthopaedic Surgeons 28(14):p e595-e603, July 15, 2020. | DOI: 10.5435/JAAOS-D-19-00700
(2) Willey, M. & University of Iowa. (n.d.). Measuring Hip Instability in Dysplastic Patients with Weight Bearing CT. Orthopedic Research Society 2022 Annual Meeting, Tampa, Florida, United States of America.

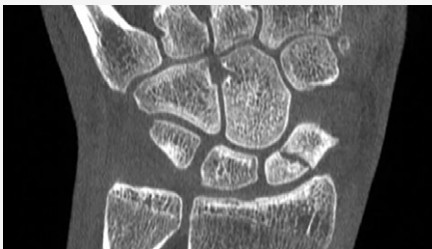

Extremity CT Imaging for Orthopedics

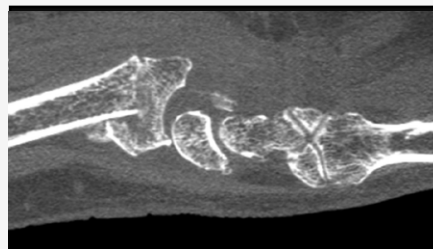
Low Dose | Comfortable Seated Position | Quick Scan Times

Common Indications

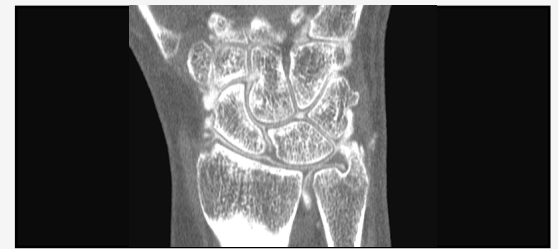Scaphoid Fracture



Distal Radius Fracture



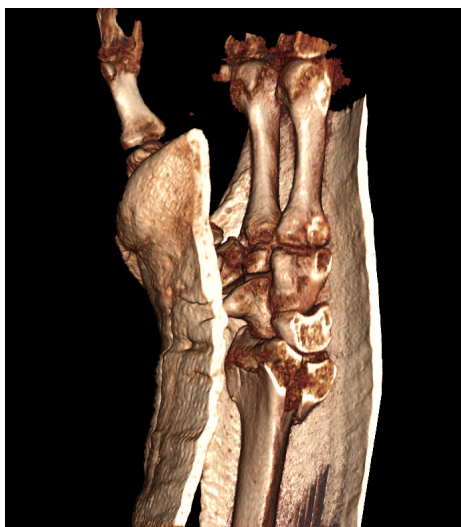TFCC Tear



- A feasible alternative to MDCT for the detection of extremity fractures at a reduced radiation dose.
- Post-operatively, CBCT can diagnose scaphoid union at an early follow-up and prevents longer immobilization and interruption of activity or work.

- Patient injected with 1cc or less of contrast, as opposed to 8-10cc required for an MRI exam.
- Patients with metal implants can obtain advanced diagnostic imaging.

Low Dose



Radiation exposure in CBCT scans have been estimated to be approximately 10-66% less than conventional CT scanners.¹

“ Considering the low dose of radiation and high image quality, CBCT could be used as a priority method of choice to assess the structure of wrist and hand bones and be done as the first step in diagnostics, replacing standard radiography. ”

A.Yu. Vasiliev, et al. Int Journal of Biomedicine

(1) Conti, Matthew S. MD; Ellis, Scott J. MD. Weight-bearing CT Scans in Foot and Ankle Surgery. Journal of the American Academy of Orthopaedic Surgeons 28(14):p e595-e603, July 15, 2020. | DOI: 10.5435/JAAOS-D-19-00700